

---

**Clare Rusbridge** BVMS PhD DipECVN MRCVS  
European and RCVS and European Specialist In Veterinary Neurology  
**Stone Lion Veterinary Centre**  
41 High Street,  
Wimbledon,  
London, SW19 5AU  
Tel: +44 (0)208 946 4228  
E-mail: [neuro.vet@btinternet.com](mailto:neuro.vet@btinternet.com)

---

Date: 18/11/2008

To whom it may concern:

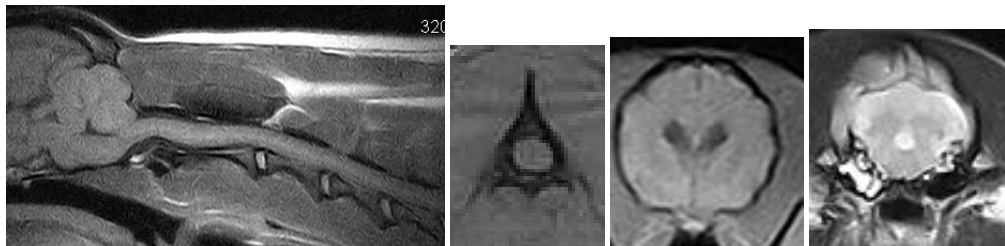
This is to confirm that on the above date the magnetic resonance images (MRI) obtained on 21<sup>st</sup> October 2008 from the tricolour cavalier King Charles spaniel detailed below were reviewed

**Trusties Zingaro**  
**Registration number NHSB 2409387**

**DOB:** 10<sup>th</sup> July 2002  
**Sex:** male  
**Microchip:** 528140001272731  
**Owner:** D A Schuller Kuyper

These images reveal:

Chiari-like malformation of the caudal skull	<b>YES</b>
Syringomyelia in the cervical spinal cord	<b>NO</b>
Central canal dilatation	<b>NO</b>
Ventricular dilatation	<b>MILD</b>
Mucoid material in <b>RIGHT</b> tympanic bullae	



Using the informal CKCS CM/SM classification the grade of **A** would be attributed to this individual.

Clare Rusbridge BVMS PhD DipECVN MRCVS  
RCVS and European Specialist In Veterinary Neurology