

Reported by **Clare Rusbridge** BVMS PhD DipECVN MRCVS
European and RCVS and European Specialist In Veterinary Neurology

Stone Lion Veterinary Hospital

41 High Street,

Wimbledon,

London, SW19 5AU

Tel: +44 (0)208 946 4228

Date: 11/07/2011

To whom it may concern:

This is to confirm that on the above date the magnetic resonance images (MRI) of **Sandbrae Bolt from the Blue** (Ewan)– **AJ03699701** obtained on **22nd June 2011** were reviewed

Ruby CKCS male, **DOB 15th July 2008**, microchip 956000001585017

Owner – **Mrs E Glen**

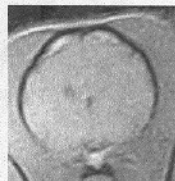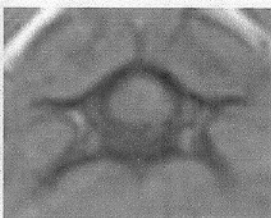
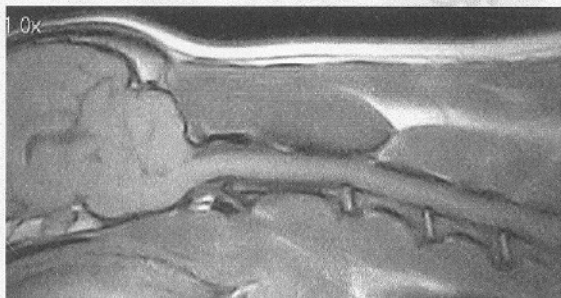
These images reveal:

Chiari like malformation of the caudal skull **YES**

Dilatation of the central canal / syringomyelia **NO**

Ventricular dilatation **MILD**

Mucoid material in **RIGHT** tympanic bullae



This dog was **2.9 years old** at the time of scanning. Using the informal CKCS classification scheme the grade of **A** would be attributed to this individual.

Clare Rusbridge BVMS PhD DipECVN MRCVS
RCVS and European Specialist In Veterinary Neurology

For information on all aspects of syringomyelia visit
<http://www.veterinary-neurologist.co.uk>

